



Pediatric esophageal perforation due to firearm injuries during the Syrian war and a new suture technique



Ahmet Atıcı^{a,*}, Mehmet Emin Çelikkaya^a, Çiğdem El^b, Bülent Akçora^a

^a Mustafa Kemal University, School of Medicine, Department of Pediatric Surgery, 31124, Antakya, Hatay, Turkey

^b Mustafa Kemal University, School of Medicine, Department of Pediatrics, 31124, Antakya, Hatay, Turkey

ABSTRACT

The incidence of esophageal perforation (EP) due to firearm injury (FAI) is markedly low compared with that occurring in other organs. The most frequently reported cause of EP is iatrogenic injuries. The incidence of EP due to penetrating injuries, such as FAI, is very rare and highly destructive. Here we report cases of EP due to FAI in childhood during the Syrian war and elucidate a new suture technique.

1. Introduction

The incidence of esophageal perforation (EP) due to firearm injury (FAI) is markedly low compared with that occurring in other organs [1]. Typically, EP can be reported in situations like childhood trauma, dilatation due to esophagus stricture, endoscopic interventions, especially the neonatal period endotracheal intubation, during nasogastric catheterization, transesophageal echocardiography, swallowing caustic agent, and compulsive vomiting [2–7]. However, the incidence of EP due to penetrating injuries, such as FAI, is very rare (0.7%) and highly destructive [6,8]. The most frequently reported cause of EP is iatrogenic injuries (71%–84%) [1,3,7]. Here we report cases of EP due to FAI in childhood during the Syrian war and elucidate a new suture technique (Bakçora). (see Table 1).

2. Case 1

An 11-year-old male patient was referred to our hospital's emergency service because of a bomb explosion in Syria. The findings of the physical examination were as follows: general medical condition, good; SaO₂, 80%; body heat, 38.2 °C; pulse, 102/min; respiration rate, 34/min; and blood pressure, 110/60 mmHg. Computed tomography (CT) revealed the orally administered contrast material extravasation between the pulmonary parenchyma and visceral pleura on the distal part of the esophagus. Accordingly, we applied an intravenous solution and a wide-spectrum antibiotic (ceftriaxone/flagyl) to the patient, who was operated immediately. Primarily, we performed esophagoscopy, which revealed a linear laceration on the thoracic esophagus (Fig. 1A, yellow arrow). Subsequently, we performed a left thoracotomy, and an approximately 9-cm long well-circumscribed perforation extending on the

longitudinal axis was observed on the central section of the esophagus (Fig. 1B, arrow). Accordingly, the perforation was repaired with Bakçora suture (Fig. 1C), and the patient was nourished because no leakage was reported on an esophagogram at postoperative day 7. On postoperative day 9, the patient was discharged uneventfully.

3. Case 2

A 7-year-old female was referred to our hospital because of FAI that occurred 2 h ago. Physical examination revealed her bad general medical condition; she was intubated and her SaO₂ was 92%, body heat was 36.5 °C, pulse was 112/min, respiration rate was 34/min, and blood pressure was 110/60 mmHg. In addition, a 1-cm diameter tissue defect was observed that had an inlet hole close to the mandible on the cervical midline (Fig. 2). We applied an intravenous solution and a wide-spectrum antibiotic (ceftriaxone/flagyl) to the patient and was subsequently operated urgently. An approximately 0.5-cm perforation was present near the anterior access of the esophagus. In addition, we observed that the skin defect and esophagus were related. No pathology was observed on bronchoscopy. We performed a 4-cm incision by extending the inlet hole on the cervical midline to the left. Further exploration revealed that the esophagus was seemingly ruptured entirely. We anastomosed with 4/0 pds (absorbable suture) and Bakçora sutures end-to-end. The patient was transferred to the intensive care unit in the intubated state. On postoperative day 7, the patient was extubated and on postoperative day 8, she was given food orally. Finally, the patient was discharged on postoperative day 17.

* Corresponding author.

E-mail addresses: ahmetatici06@gmail.com, ahmetim1501@hotmail.com (A. Atıcı).

Table 1
Summarizes the primary diagnosis and information of all patients.

Patients	Age (year)/ Sex	Primer Diagnosis	Operation 1	Operation 2	Complication	Time of Feding/day	Time of hospitalization/ day	Results
1	11 Y/M	Firearm injury	Left thoracotomy/Primary repair with Bakçora suture	–	None	7	9	Cure
2	7 Y/F	Firearm injury	Side to side anastomosis with Bakçora suture	–	None	8	17	Cure
3	10 Y/M	Firearm injury	Primary repair	Side to side anastomosis with Bakçora suture	Recurrence	9	22	Cure
4	4 Y/M	Firearm injury	Primary repair and flap	–	None	33	42	Cure

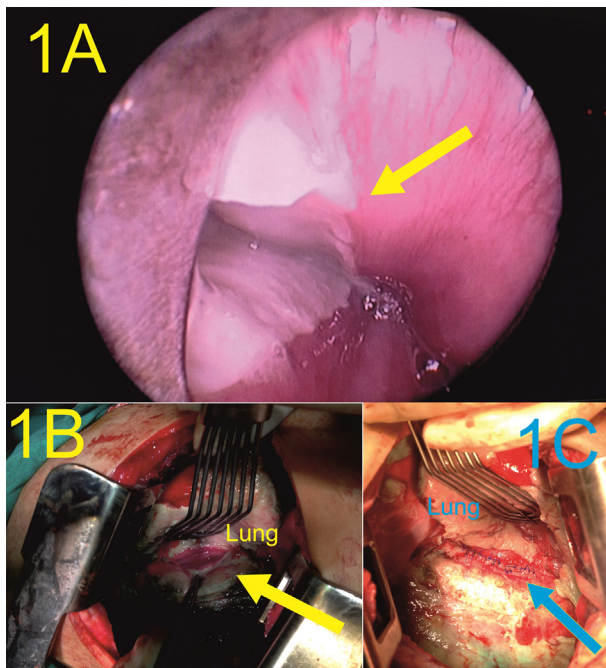


Fig. 1. A: A linear laceration on thoracic esophagus was observed in esophagoscopy. B: Approximately 9-cm long well-circumscribed perforation extending on the longitudinal axis was observed on the central section of the esophagus. C: Perforation was repaired with Bakçora suture.

4. Case 3

A 10-year-old male patient was referred to our hospital because of FAI. Based on his physical examination, his general medical condition was bad and body heat was 36.4 °C, SaO₂ was 80%–88%, pulse was 136/min, the respiration rate was 28/min, and the blood pressure was 107/45 mmHg. We were informed that the patient was injured approximately 12 h ago and had undergone a surgery in Syria. There was an access hole on the neck at the incisura jugularis level, 7-cm laceration, and a penrose drain on the laceration due to FAI (Fig. 3). In addition, we noted an air intake through the access hole. The bilateral chest tube was attached due to bilateral hemothorax. Besides, pneumomediastinum was detected from a direct graph. Accordingly, the patient was operated urgently. Esophagoscopy revealed that the restorations were performed on the esophagus anterior and posterior wall at the incisura jugularis level. We examined the patient through the same incision and found sutures belonging to reparation on the anterior wall of the esophagus and trachea left lateral. Moreover, there was an active air leakage from the trachea. Accordingly, we performed a reparation with 3/0 vicryl and put primer supportive sutures on the anterior side of the esophagus. Then, the patient was transferred to the intensive care unit in the intubated state. On postoperative day 3, we reexamined the patient because of saliva leakage from the incision. During the second operation, we detected a longitudinal perforation (3-

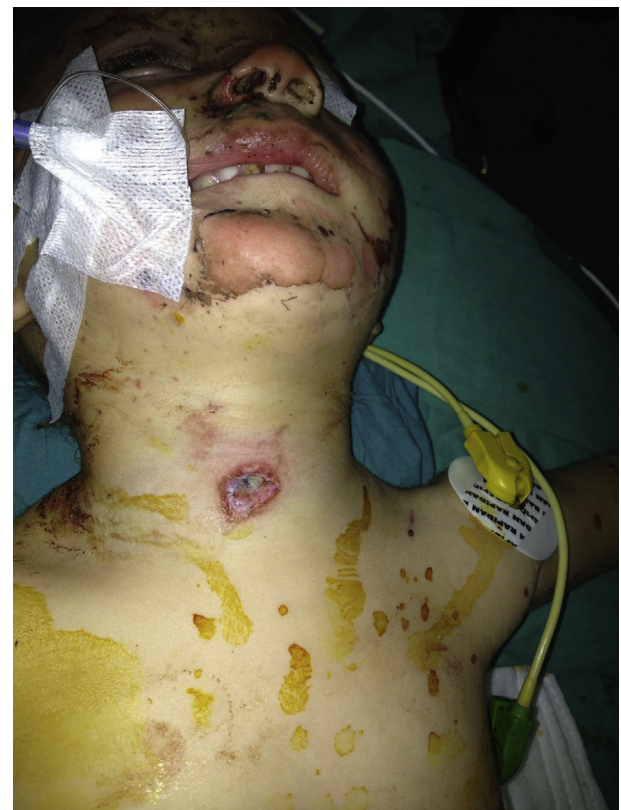

Fig. 2. Approximately a 1-cm diameter tissue defect was observed that had an inlet hole close to the mandible on the cervical midline.

cm long) on the esophagus posterior wall, which was not observed in the first operation. Anastomose sutures were obtained from the esophagus anterior wall. We resected the defected part of the esophagus using 2/0 vicryl and performed the Bakçora sutures end-to-end anastomoses. On postoperative day 7, no leakage was observed. Although chest tubes were removed on postoperative day 8, the patient was nourished on postoperative day 9. Finally, the patient was discharged uneventfully on postoperative day 22.

5. Case 4

A 4-year-old male patient was referred to our hospital because of FAI that had occurred 6 h ago. The findings of physical examination were as follows: body heat, 37.4 °C; SaO₂, 100%; 130/min pulse; respiration rate, 55/min; and blood pressure, 128/66 mmHg. His general condition was bad, and he was intubated. We observed an access hole on the thyroid cartilage (diameter, 0.5 mm; Fig. 4A). The patient was placed in the intensive care unit and was followed up conservatively. On day 5, the patient's body temperature soared up to 39 °C as a result of the injury. From CT, mediastinal abscess was observed. We

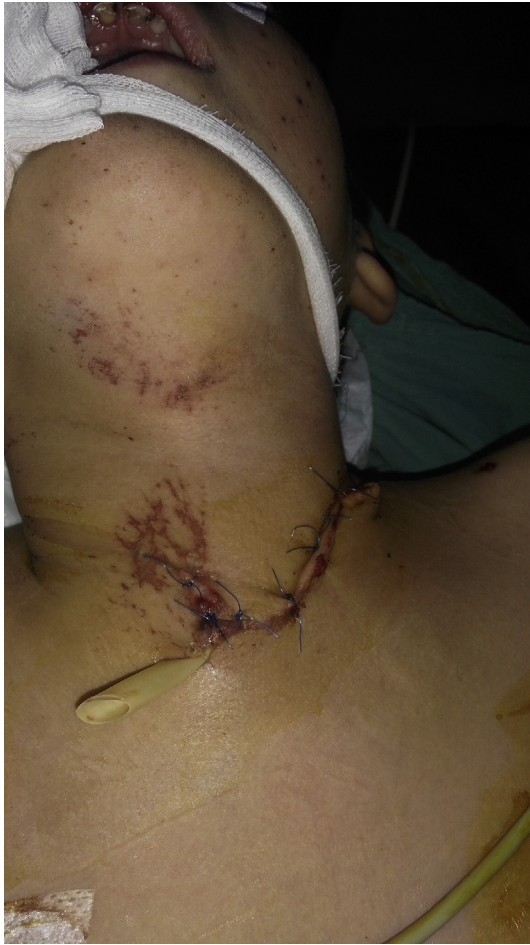

Fig. 3. There was an access hole on the neck at the incisura jugularis level, 7-cm laceration, and a penrose drain on the laceration due to FAI.

performed thoracotomy urgently from the intercostal gap because the patient was unstable. The abscess was drained, and the thorax tube was inserted into the cervical region. On day 21, the patient was provided baby food orally, but it was found to be leaking from the thorax tube. On day 25, bronchoscopy and esophagoscopy were performed again, revealing that the tracheal defect was closed spontaneously, but EP was increased to a 1-cm diameter, and severe pus and inflammation was observed around this area (Fig. 4B, arrow). We considered that EP could not be closed spontaneously and, therefore, we performed gastrostomy on the patient. On day 28, we performed a cervical dissection with a mini apron flap incision. On examination, we determined an

approximately 1.5-cm defect by methylene blue on the posterolateral cervical esophagus. Around the fistula, the granulation tissue was cleaned and the defect was repaired. In addition, a flap was prepared from the strep muscles and covered over the defect as a support. On day 33, the patient was fed successfully, and no leakage was observed on the esophagogram. On day 34, the thorax tube was removed. Finally, on day 42, the patient was discharged uneventfully.

6. Discussion

Lately, the damage level and its variety incurred during war have changed drastically because of the use of high kinetic energy guns and the impact and velocity of these guns on organs and the biological system [9]. Shrapnel and blast injuries constitute the physiopathology. Broadly, blast injuries are of four types. The first type of injury occurs because of an exposure to a blast wave. In this case, the first incarceration and later expansiveness occur on the affected organs, resulting in the deterioration of soft tissue and cell membranes. Our first case belonged to this type of injury. The second type of injury occurs because of a blunt trauma and blast wave crush of low-weight particles. The third injury occurs when the blast wave reaches adequate energy levels and expels high-weight materials. The fourth type of injury does not comply with other injury types and includes injuries such as flash burns [10]. Our second case belonged to the fourth type because of the presence of a bilateral eardrum perforation and second-degree flash burns on the face (Fig. 2). In shrapnel injuries, the severity of an injury changes according to the distance between the patient and the gun because the shrapnel speed decreases with time. In this report, cases 3 and 4 presented shrapnel injuries.

The possibility of EP due to FAI in children is extremely rare [11–13]. Recently, two studies reported the incidence of injuries because of FAI to be 83% and 70%, respectively, whereas cervical injuries comprised the least of those injuries (3%–6%) and EP was not reported [9,10]. Another study on 1916 cases reported EP in two of its 223 patients who had a cervical injury during their childhood; in addition, EP due to FAI was indicated to be 0.7%. Another study on 77 patients with cervical injury reported only one patient with EP [8,14,15]. In this study, we reported the EP incidence to be 0.4% among patients with FAI.

The esophagus has a relatively less blood supply, does not have serosa, and comprises less supportive tissue around because the esophagus comprises a thin wall; thus, the possibility of perforation, spreading of infection, mediastinitis, abscess, and eventual multiple organ failure is high [3]. Clinically, the leading symptom is dysphagia (60%), followed by fever and dyspnea. Vomiting, chest pain, and subcutaneous emphysema, known as Mackler's triad, are also expected during examination [16]. We observed most of these symptoms in our patients. Of note, an early diagnosis and treatment, along with the

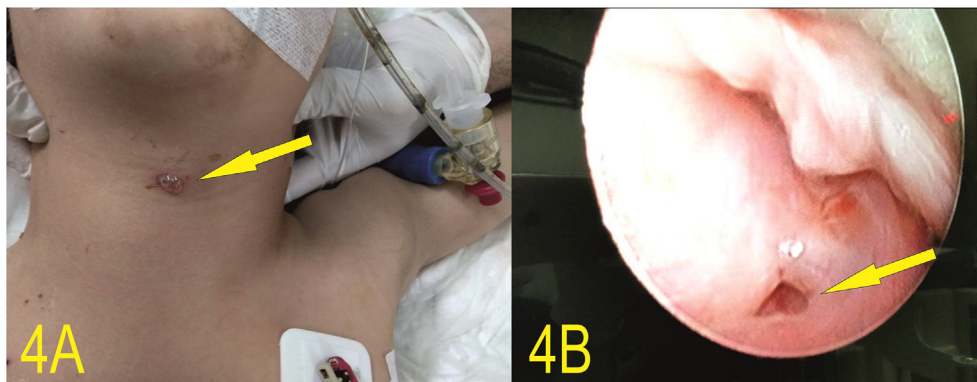


Fig. 4. A: Approximately 0,5 mm acces hole observed on the thyroid cartilage. B: Approximately 1-cm diameter, and severe pus and inflammation was observed around this area.

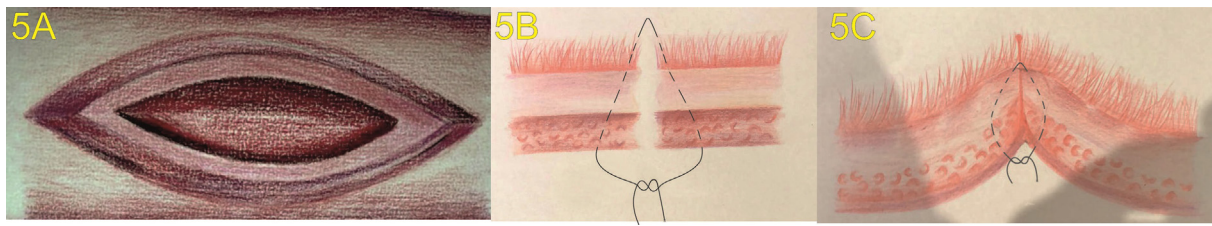


Fig. 5. A: Esophageal perforation. B: Broader and thicker sutures are attached to the seromuscular layer and thinner and close-to-the-end sutures are attached to the mucosa. C: Seromuscular structure provides perforated area like sutures with Lambert averted.

injured part, size of the perforation area, and its contamination are imperative for the prognosis [1,17]. After 12–24 h, in case of delayed diagnosis, saliva and bacterial extravasation, defect's acid, pepsin, and bile reflux cause peripheral tissue loss, infection, and subsequent necrosis [1,2], ultimately resulting in mediastinitis and sepsis rapidly because of the negative intrathoracic pressure.

For diagnosis, the various analyses used are, graphy with contrast, rigid endoscopy, and CT. For EP, pneumothorax, pleural effusion, subcutaneous emphysema, pneumopericardium or pneumomediastinum, and abnormal localized nasogastric tube can be determined from direct graphies [18]. In our patients, most of these symptoms were detected. However, direct graphs cannot provide findings in the ratio of 12%–23% [2]. Similarly, an esophagogram can provide a false negative result at a level of 10%. From CT, extraluminal air, paraesophageal liquid, wall thickening, intramural hematoma, and extraluminal contrast can be detected.

Several treatment options are available for EP depending on the patients' age and type of injury. In recent years, non-operative treatment has gained recognition [1,6,18]. For stable patients and those with iatrogenic injuries, conservative treatment is recommended, followed by surgical intervention after 24 h [5]. However, some studies have reported the mortality rate of the conservative approach to be 7%–36% [5,18]. Assumedly, EP due to FAI injuries are unique injuries with two times more leakage and mediastinal abscess risk [6]. Our fourth case with a tiny (0.5 cm) cervical EP underwent preliminary conservative treatment first and required surgical treatment later; this situation is associated with FAI being an injury with kinetic energy. Thus, we recommend selecting the conservative treatment cautiously for tiny perforations due to FAI.

During EP, although single-layer reparation is recommended for pediatric cases undergoing surgical treatment, a two-layer reparation is recommended for adults (first layer, mucosal repair with absorbable sutures; second layer, muscle closure with non-absorbable sutures) [1,2,4,19]. Various tissues are used for strengthening primary reparations such as intercostal, mental, pericardial fat pad, diaphragmatic pedicle graft, rhomboid muscle, latissimus dorsi muscle, and pleural flap [1,2,4,19]. For EP, during surgical treatment, along with classical primary reparation and end-to-end anastomoses, other suture techniques are recommended for increasing the stability of sutures [19,20]. We applied the Bakçora suture, a one-layer suture technique that has not been defined previously, to our patients because we believe that it is safer for EP and the esophagus to have a unique anatomical structure (not having serosa; Fig. 5A–C). While performing classical end-to-end anastomoses or primer reparation, mucosa can be attached overlapping, not end-to-end, and the seromuscular layer cannot be supported. In addition, we believe that this situation can adversely affect wound healing and leakage rate. In the Bakçora suture, broader and thicker sutures are attached to the seromuscular layer and thinner and close-to-the-end sutures are attached to the mucosa; in addition, the seromuscular structure provides perforated area like sutures with Lambert averted (Fig. 5A–C). Although one of our patients with EP, on whom we performed Bakçora suturing, was diagnosed on day 4, mortality was not observed in any of our patients.

In conclusion, pathophysiology and mechanics of EPs due to FAI are

very different from other causes of EP. Thus, conservative treatment for patients with EP due to FAI should be selected judiciously and applied to patients meticulously. For patients with EP due to high-kinetic-energy-level FAI, we recommend the Bakçora suture because this method is safer for esophagus reparation. However, the assessment of the extensive number of patients is required to validate the ideal suture technique and treatment method for EP.

Patient consent

Consent to publish the case report was not obtained. This report does not contain any personal information that could lead to the identification of the patient.

Funding

No funding or grant support.

Authorship

All authors attest that they meet the current ICMJE criteria for Authorship.

Conflict of interest

The following authors have no financial disclosures.

References

- [1] Mandiba TE, Muckart JJ. Penetrating injuries to the cervical oesophagus: is routine exploration mandatory? *Ann R Coll Surg Engl* 2003;85(3):162.
- [2] Rentea RM, Peter SD. Neonatal and pediatric esophageal perforation. *Seminars in pediatric surgery*, vol. 26. Elsevier; 2017. p. 87–94. 2.
- [3] Gander JW, Berdon WE, Cowles RA. Iatrogenic esophageal perforation in children. *Pediatr Surg Int* 2009;25(5):395–401.
- [4] Weiman DS, Pate JW, Walker WA, Brosnan KM, Fabian TC. Combined gunshot injuries of the trachea and esophagus. *World J Surg* 1996;20:1096–100.
- [5] Mishra B, Singhal S, Aggarwal D, Kumar N, Kumar S. Non operative management of traumatic esophageal perforation leading to esophago cutaneous fistula in pediatric age group:review and case report. *World J Emerg Surg* 2015;10:19.
- [6] Armstrong WB, Detar TR, Stanley RB. Diagnosis and management of external penetrating cervical esophageal injuries. *Ann Otol Rhinol Laryngol* 1994;103:863–71.
- [7] Martinez L, Rivas S, Hernandez F, Avila LF, Lassaletta L, Murcia J, et al. Aggressive conservative treatment of esophageal perforations in children. *J Pediatr Surg* 2003;38:685–9.
- [8] Cornwell EE, Kennedy F, Ayad IA, Berne TV, Velmahos G, Asensio J, et al. Trans mediastinal gunshot wounds: a reconsideration of the role of aortography. *Arch Surg* 1996;131:949–52.
- [9] Şimşek BK, Dokur M, Uysal E, Çaliker N, Gökçe ON, Deniz İK, et al. Characteristics of the injuries of Syrian refugees sustained during the civil war. *Ulus Travma Acil Cerrahi Derg* 2017;23(3):199–206.
- [10] Logan NJ, Arora H, Higgins CA. Evaluating primary blast effects in vitro. *J Vis Exp* 2017;127:55618.
- [11] Campbell NM, Colville JG, Van der Heyde Y, Van As AB. Firearm injuries to children in Cape Town, South Africa: impact of the 2004 firearms Control Act. *S Afr J Surg* 2013;51(3):92–6.
- [12] Senger C, Keijzer R, Smith G, Muensterer OJ. Pediatric firearm injuries: a 10-year single-center experience of 194 patients. *J Pediatr Surg* 2011;46(5):927–32.
- [13] McBride DL. Pediatric firearm deaths and injuries in the United States. *J Pediatr Nurs* 2017;38:138–9.
- [14] Van as AB, Manganyi R, Brooks A. Treatment of thoracic trauma in children: literature review, Red Cross War Memorial Children's Hospital data analysis, and

- guidelines for management. *Eur J Pediatr Surg* 2013;23(6):434–43.
- [15] Van Waes OJ, Cheriex KCAL, Navsaria PH, van Riet PA, Nicol AJ, Vermeulen J. Management of penetrating neck injuries. *Br J Surg* 2012;99(1):149–54.
- [16] Makhani M, Midani D, Goldberg A, Friedenber FK. Pathogenesis and outcomes of traumatic injuries of the esophagus. *Dis Esophagus* 2014;27(7):630–6.
- [17] Bernadette NN, Ze JJ, Pandy AO, Kalla CM, Kamgaing N, Eone DH. Long standing esophageal perforation due to foreign body impaction in children: a therapeutic challenge in a resource limited setting Case reports in pediatrics 2017
- [18] Onwuka EA, Saadai P, Boomer LA, Nwomeh BC. Nonoperative management of esophageal perforations in the newborn. *J Surg Res* 2016;205(1):102–7.
- [19] Saad SA, Othersen HB. Esophageal perforation in an infant: repair with a pleural flap. *South Med J* 1979;72:1596–8.
- [20] Di Carlo I, Toro A, Burrafato G, Gayet B. Repair of esophageal perforation: a new technique. *Can J Surg* 2008;51:71–2.